INFECTIONS

Nick Blanas, BSc,DDS,FRCD(C)
Email: nick.blanas@sunnybrook.ca

Etiology

- Caries.
- Periodontal disease.
- Bone.
- Lesions.

THE SUNDAY STAR

Cloudy; isolated showers. High 7 C

March 1, 1998

www.thestar.com

Death of a toothache victim

How tragic errors in hospital doomed man, 24

By Rita Daly
Health Reporter

On a cold February night, Olga Bowen squeezed her son's hand goodbye as he lay in a Toronto hospital bed. She promised to return in the morning.

The tall, robust 24-year-old couldn't smile back. But Bowen remembers, it being the last time she saw him alive, he said goodbye.

It hurt like hell to talk. A festering toothache swelled his throat and neck so badly, the family doctor who probed inside his mouth early that afternoon said they should go straight to the hospital emergency.

They did, of course, and a doctor at Toronto Hospital's Western division did the same sort of probing and ordered neck x-rays before sending Bowen's son by ambulance to the main hospital downtown.

Sunday Special

There, a third doctor examined the young man's mouth, prescribed painkillers and then admitted him for observation in a room, a step-down unit of intensive care, for the night.

Seven hours later, he died.

He was born Donald David Vanriel. And his death was one of those tragedies that normally goes unnoticed in this city's hospitals.

Things go wrong. Hospitals get busy or there's a money squeeze. Or the system just takes over and performs its assembly-line ritual day in and day out until, suddenly, a person dies unexpectedly.

In Vanriel's case, errors would be made, a coroner's probe would occur and potential life-saving changes would follow for patients to come.

Meanwhile, the burden of his unforeseen death would fall heavily on the people closest to him. People like Olga Bowen.

Ever since she got the call waking her at 4:30 a.m. and telling her to come straight away, Bowen has ached to find a logical explanation for her son's death. She can find none. She has trouble sleeping and her blood pressure acts up whenever she searches for answers to the questions whirling inside her head.

Why did he die, when he was always so healthy and strong? And how could it happen only hours after she left him in the capable hands of doctors and

DAVID VANRIEL

Etiology

- Post-surgical:
  - Tooth extraction.
  - Periodontal surgery.
  - Endodontic therapy (conventional and surgical).
  - Biopsy/excision of lesions.
  - Pre-prosthetic and implant surgery.
  - Maxillofacial surgery.

Etiology

- Traumatic:
  - Laceration.
  - Fractures.
  - Oral piercing.
  - Oral tattooing.
  - Tongue/cheek bite.

Signs and Symptoms - Local

- Pain.
- Heat.
- Swelling.
- Redness.

Signs and Symptoms - Regional

- Enlarged lymph nodes.
- Dysphagia.
- Dyspnea.
- Odynophagia.
- Visual changes.
- Neurologic changes.
- Chest pain.
- Draining fistula.

Signs and Symptoms - Systemic

- Fever.
- Malaise.
- Dehydration.
- Diaphoresis (pallor, sweats).
- Rigors (chills).

Microbiology

- Mixed (aerobic/anaerobic) colonies.

Pathophysiology

- Cellulitis.
- Abscess.

ASSESSING THE INFECTED PATIENT

History

- The most important part of the assessment.
- How does the patient feel overall?
- Timing of symptoms?

History

- For post-extraction infections:
  - Difficulty of extractions.
  - Previous infection in tooth/teeth.
  - Compliance with instructions.

Extra-oral exam

- Visible swelling? Size? Fluctuance?
- Is the inferior border of the mandible palpable from the midline to the angles?
- Are the eyes swollen shut?
- Watch the patient swallow their saliva.
- Is the swelling close to the skin?

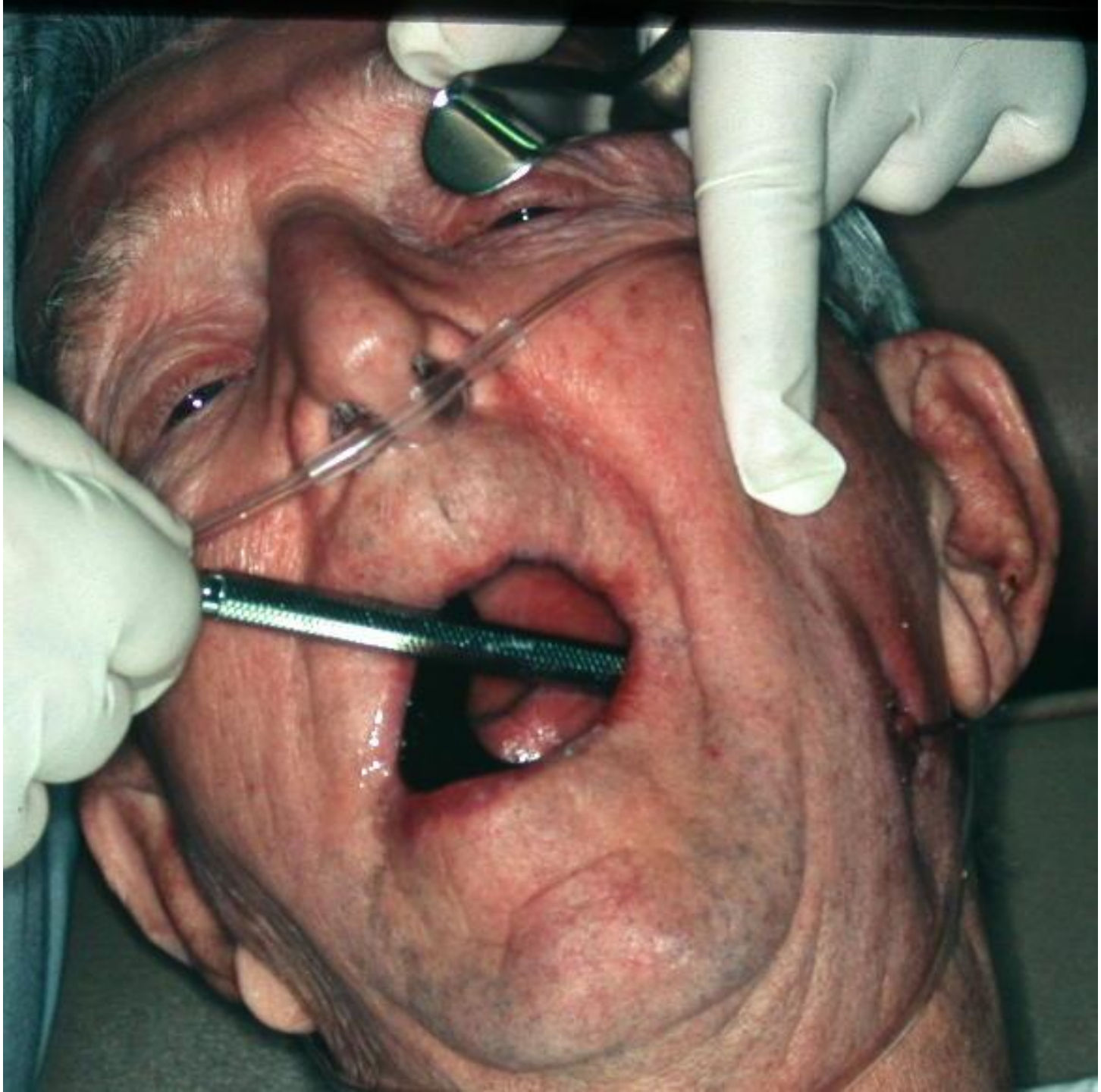



Intra-oral Exam

- Trismus.
- Swelling; size; fluctuance.
- Elevation of floor of mouth and tongue.
- Swelling of pharynx.
- Deviation of uvula.

Diagnostic Testing

- Radiology:
  - Plain films.
  - CT, MRI.
  - Bone scans.
  - Angiography.
- Bacteriology:
  - Culture and sensitivity testing.
  - Gram staining.

Treatment

- Medical.
- Surgical.

Medical Management

- Control conditions which compromise host resistance.
- Supportive care.
- Augment host resistance – antibiotics.

Penicillin Vk

- First line antibiotic that is still very effective at treating odontogenic infections.
- Early infection.
- Mild infection.
- (Patient with limited finances).

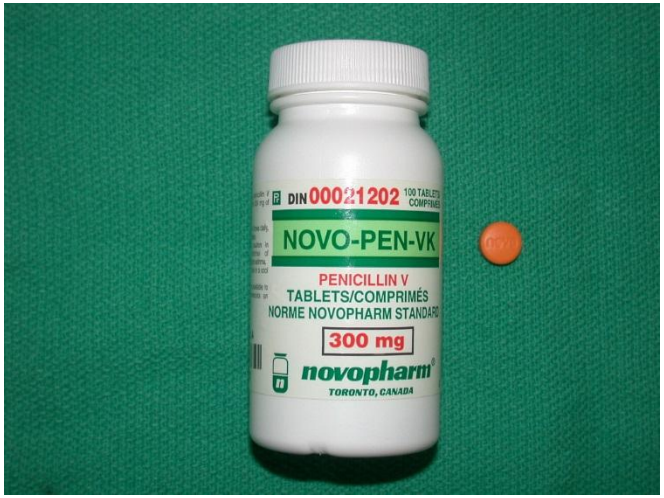

Amoxicillin

- Early infection.
- Mild infection.
- Possible sinus involvement.
- Patient in whom compliance is an issue.

Metronidazole

- Don’t prescribe this on its own.
- Add to Penicillin in more severe infections.
- Add to Penicillin if there is no improvement after 3 days.
- Avoid in alcoholics.

Clindamycin

- First line antibiotic for patients allergic to penicillin.
- Severe infections.
- Be aware of pseudomembranous colitis.

Mild/Early Infections

Mild/Early Infections

- Penicillin Vk 600 mg qid x 7 days or,
- Amoxicillin 500 mg tid x 7 days.

- If not responding, give Clindamycin 300 mg qid x 7 days.
- If penicillin allergic, go straight to Clindamycin.

Severe/Advanced Infections

Severe/Advanced Infections

- Penicillin Vk 600 mg qid x 7 days and,
- Metronidazole 500 mg bid x 7 days.

- If not responding, switch to Clindamycin.
- If Penicillin allergic, go straight to Clindamycin.

Non-responsive Infections

- Consider adding PenicillinVk or Ciprofloxacin to Clindamycin.
- May have to consider intravenous antibiotics, hospital admission, surgery, etc.
- By this point, patient should be under the care of a specialist.

Odontogenic Infections Involving the Maxillary Sinuses or the Skin

- Amoxicillin 500 mg tid x 7 days or
- Keflex 500 mg qid x 7 days.

- If Penicillin allergic, give Clindamycin.

Pregnant Patients

- Avoid drugs where possible, but you've got to treat infections!
- Penicillin, Amoxicillin, Clindamycin are considered safe.

Lactating Patients

- Penicillin, Amoxicillin, Clindamycin are considered safe.

The Elderly

- May be frail, malnurished, immunocompromised.
- May have reduced kidney function – dosages may need to be reduced.

Infants/Children

- Dehydrate quickly.
- Use level of activity as a clue as to systemic involvement.
- Amoxicillin 250 mg tid (20-50 mg/kg/day in 3 divided doses).
- Clindamycin 150 mg qid (10-30 mg/kg/day in 3-4 divided doses).

Antibiotics - Complications

- Selection of resistant strains of bacteria.
- Allergic reactions.
- Adverse reactions.
- Pseudomembranous Colitis.

Oral Steroids

- Never prescribe steroids for odontogenic infections.

Surgical Management

- Take x-ray to make sure there are no foreign objects.
- Remove cause.
- Incision and drainage.
- Airway support in severe cases.

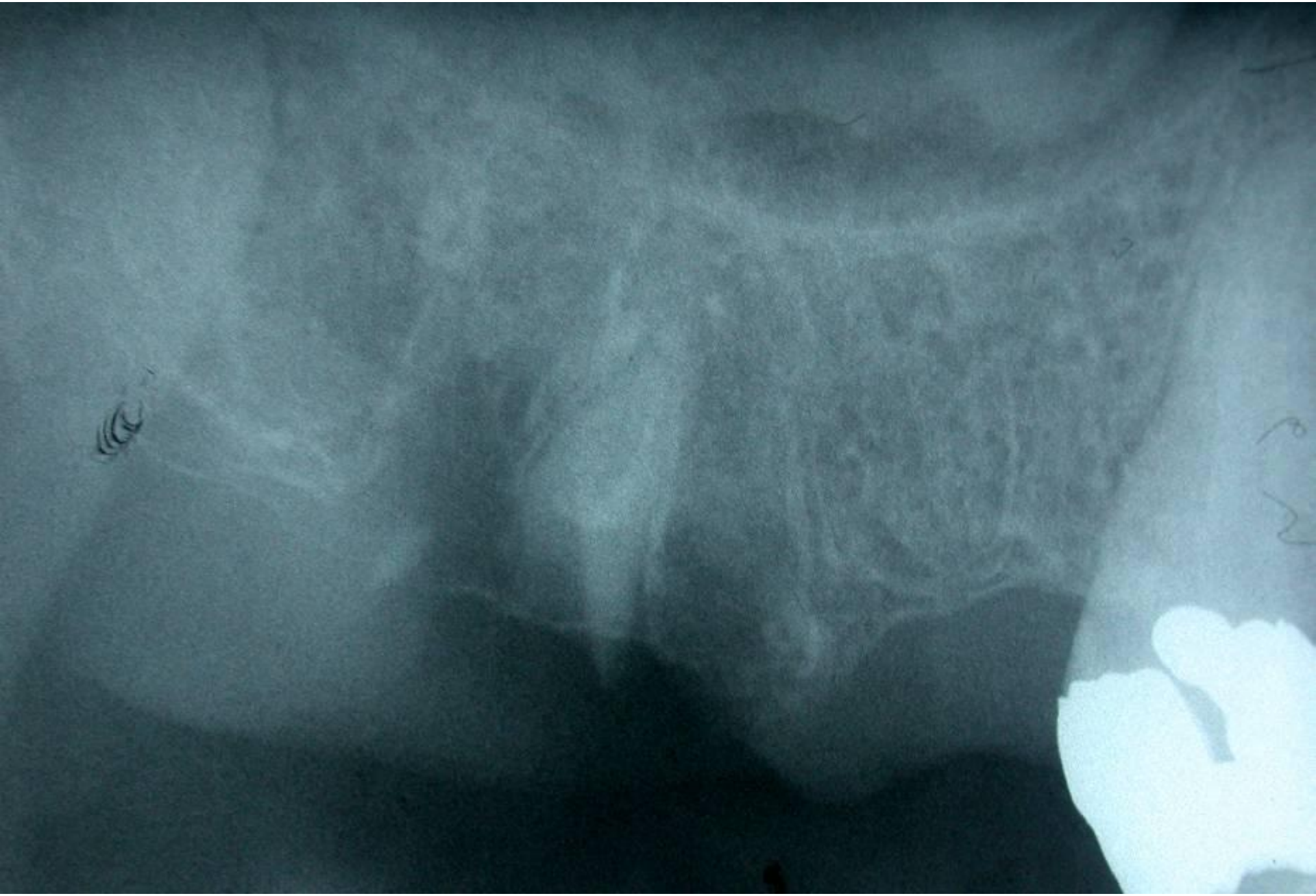

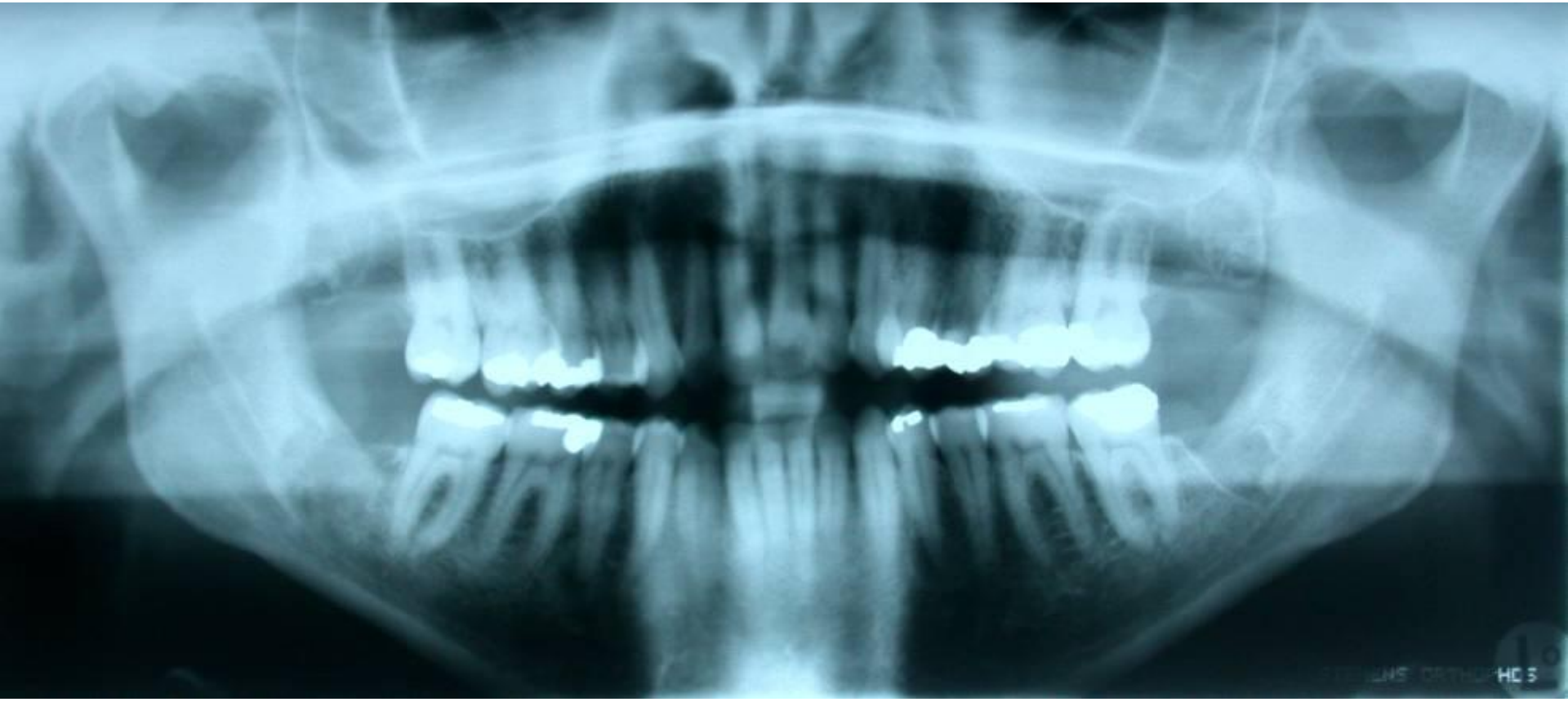
HC 3

INCISION AND DRAINAGE

Purposes

- Often necessary when an abscess has formed.
- Purposes:
  - Eliminate bacteria, bacterial products and necrotic debris.
  - Oxygenate tissues.
  - Obtain sample for C&S testing.
  - Create path for elimination of pus that may accumulate.

Instruments

Instruments cont’d.

Incision and Drainage – Intra-Oral

- Select site over area of fluctuance avoiding vital structures.
- Give lots of local and wait for it to work; block and don’t infiltrate.
- Incise through mucosa and submucosa with scalpel
- Penetrate into abscess cavity with a hemostat.
- Suture a drain to one edge of the incision.
- Remove drain in 1-2 days.

Incision and Drainage – Extra-Oral

- General anaesthesia usually required.
- Incision should be placed in non-inflammed skin.

Space Infections

Definitions

- “Potential” spaces.
- Between fasciae and underlying soft tissues.
- Fasciae – sheets of fibrous connective tissue that envelope muscles, organs and other soft tissue structures of the body.
- Several recognized spaces of the head and neck.

Pathophysiology

- How does an odontogenic infection become a space infection?
  - Caries.
  - Enamel, dentin.
  - Pulp.
  - Cancellous bone.
  - Cortical bone.
  - Soft tissues.

Pathophysiology

- Soft tissue spread occurs along the path of least resistance:
  - Boundaries are usually muscles or bones.

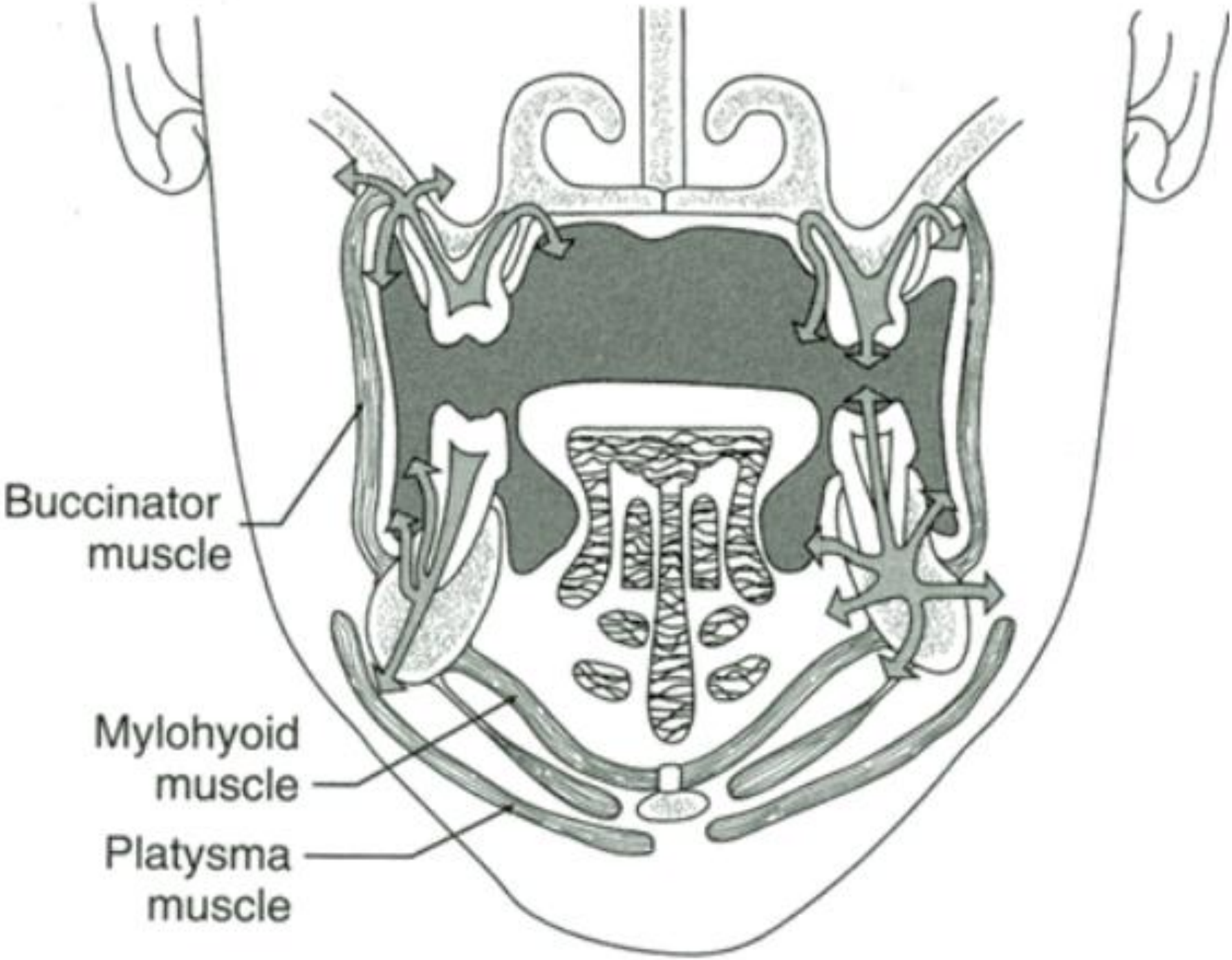
Buccinator muscle
Mylohyoid muscle
Platysma muscle

The Spaces

- Vestibular.
- Buccal.
- Submental.
- Submandibular.
- Sublingual.
- Lateral pharyngeal.

The Spaces

- Retropharyngeal.
- Pretracheal.
- Danger space.
- Submasseteric.
- Pterygomandibular.
- Superficial and deep temporal.

The Spaces

- Infraorbital/canine.
- Palatal.

Vestibular

- Between bone (maxilla or mandible) and overlying mucoperiosteum.
- Can originate from any tooth.
- Drained through a sulcular or vestibular incision.
- Painful, but otherwise of minimal consequence.

Vestibular

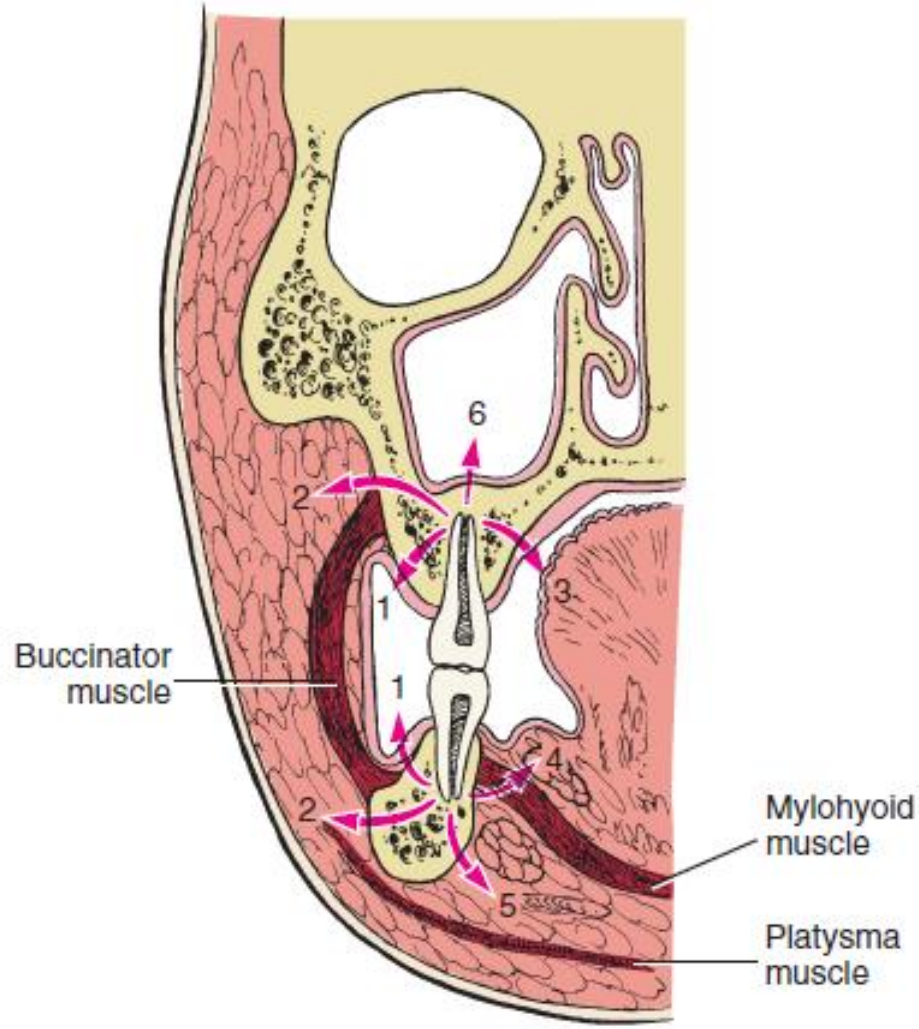

Figure 17-1 As infection erodes through bone, it can express itself in a variety of places, depending on thickness of overlying bone and relationship of muscle attachments to site of perforation. This illustration notes six possible locations: vestibular abscess (1), buccal space (2), palatal abscess (3), sublingual space (4), submandibular space (5), and maxillary sinus (6). (Adapted from Flint PW Haughey BH, Lund VJ et al, editors: *Cummings otolaryngology: Head and neck surgery*, ed 5, Philadelphia, PA, 2010, Mosby.)

Buccal

- Between the skin and buccinator muscle.
- From maxilla to mandible.
- Origin is usually any bicuspid or maxillary molars.
- Drained through an intraoral buccal mucosal incision.

Buccal

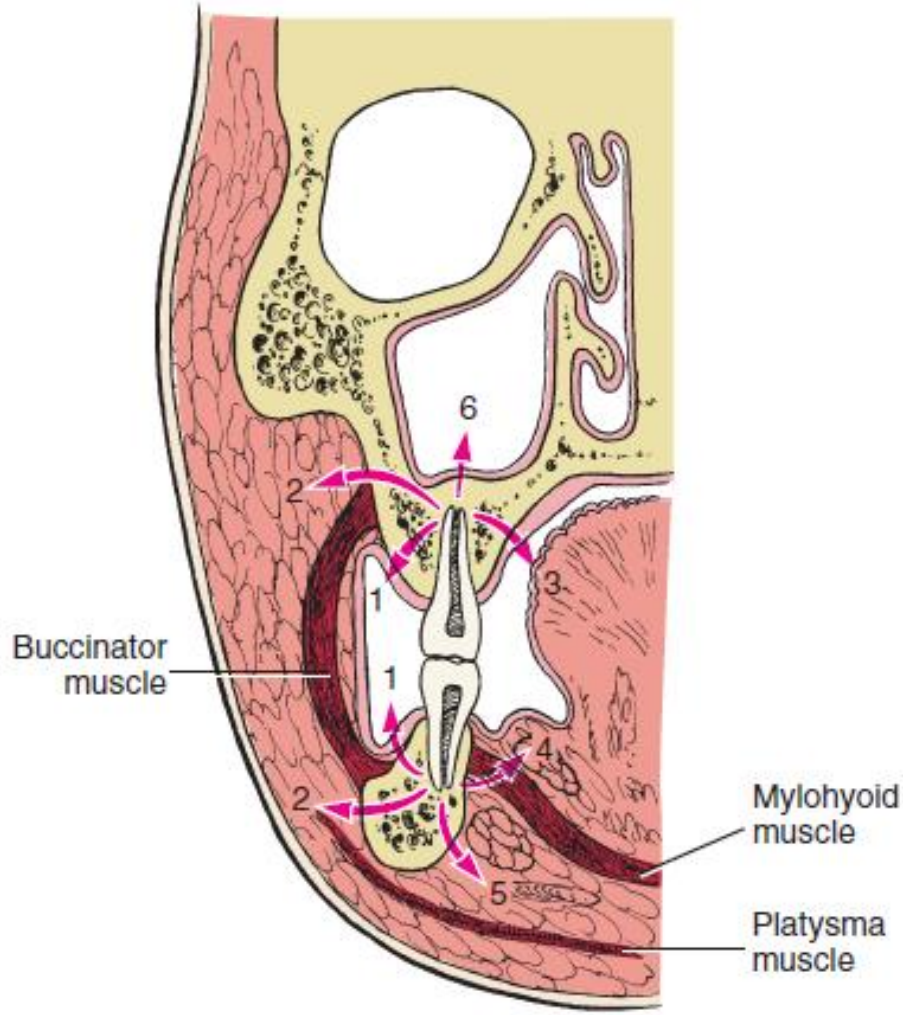

Figure 17-1 As infection erodes through bone, it can express itself in a variety of places, depending on thickness of overlying bone and relationship of muscle attachments to site of perforation. This illustration notes six possible locations: vestibular abscess (1), buccal space (2), palatal abscess (3), sublingual space (4), submandibular space (5), and maxillary sinus (6). (Adapted from Flint PW Haughey BH, Lund VJ et al, editors: *Cummings otolaryngology: Head and neck surgery*, ed 5, Philadelphia, PA, 2010, Mosby.)

Buccal

Figure 17-6 **A,** Buccal space lies between buccinator muscle and overlying skin and superficial fascia. This potential space may become involved via maxillary or mandibular molars (*arrows*). **B,** Typical buccal space infection, extending from the level of the zygomatic arch to the inferior border of the mandible and from the oral commissure to the anterior border of the masseter muscle. (**A,** Adapted from Flint PW Haughey BH, Lund VJ et al, editors: *Cummings otolaryngology: Head and neck surgery*, ed 5, Philadelphia, PA, 2010, Mosby. **B,** From Flynn TR: The swollen face. *Emerg Med Clin North Am* 15:481–519, 2000.)

Submental

- Bounded by the anterior bellies of the digastric muscles, mylohyoid muscle, mandible and platysma muscle.
- Origin is lower incisors or canines.
- Drainage is usually through a small extraoral incision.

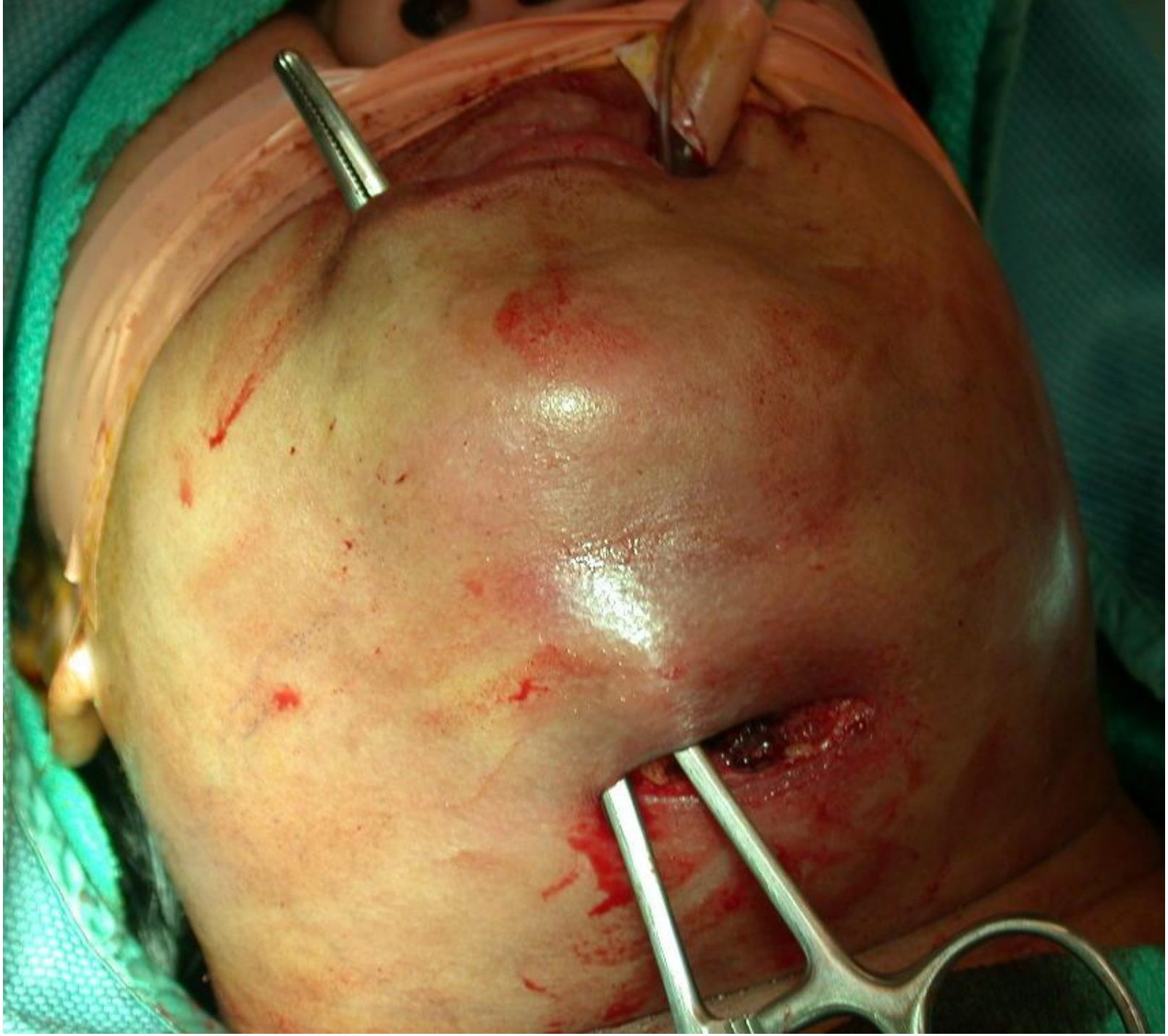

Submandibular

- Bounded by the platysma and mylohyoid muscles, medial surface of the mandible; extends to anterior belly of digastric muscle.
- Origin is usually mandibular molars.
- Drainage is through an extra-oral incision.

Submandibular

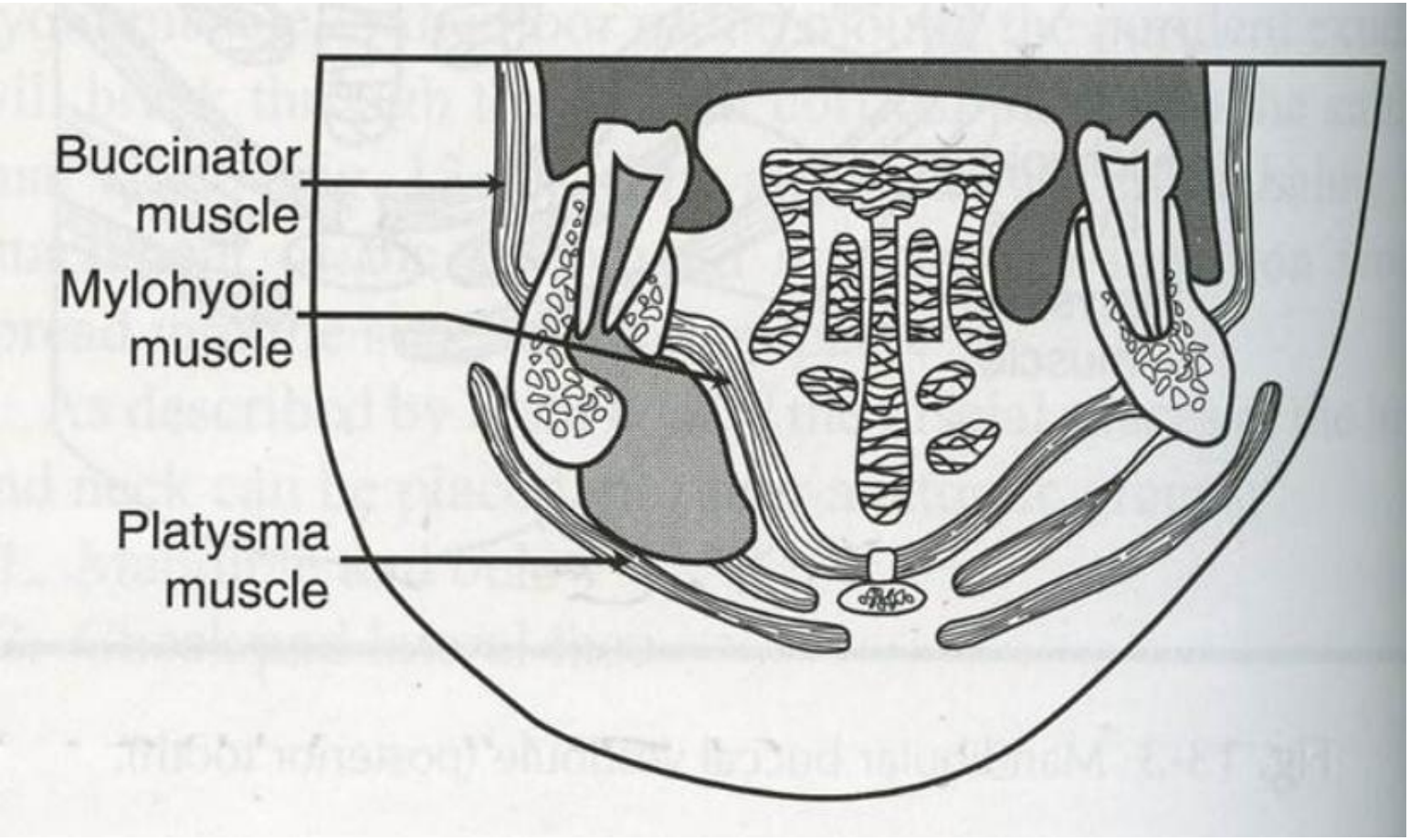

Sublingual

- Bounded by the mucosa of the floor of the mouth/tongue muscles, mylohyoid muscle, lingual cortex of the mandible.
- Continuous posteriorly with the submandibular spaces.
- Origin is usually lower bicuspids or molars or direct trauma.
- Drained is through intraoral or extraoral incisions.

Sublingual

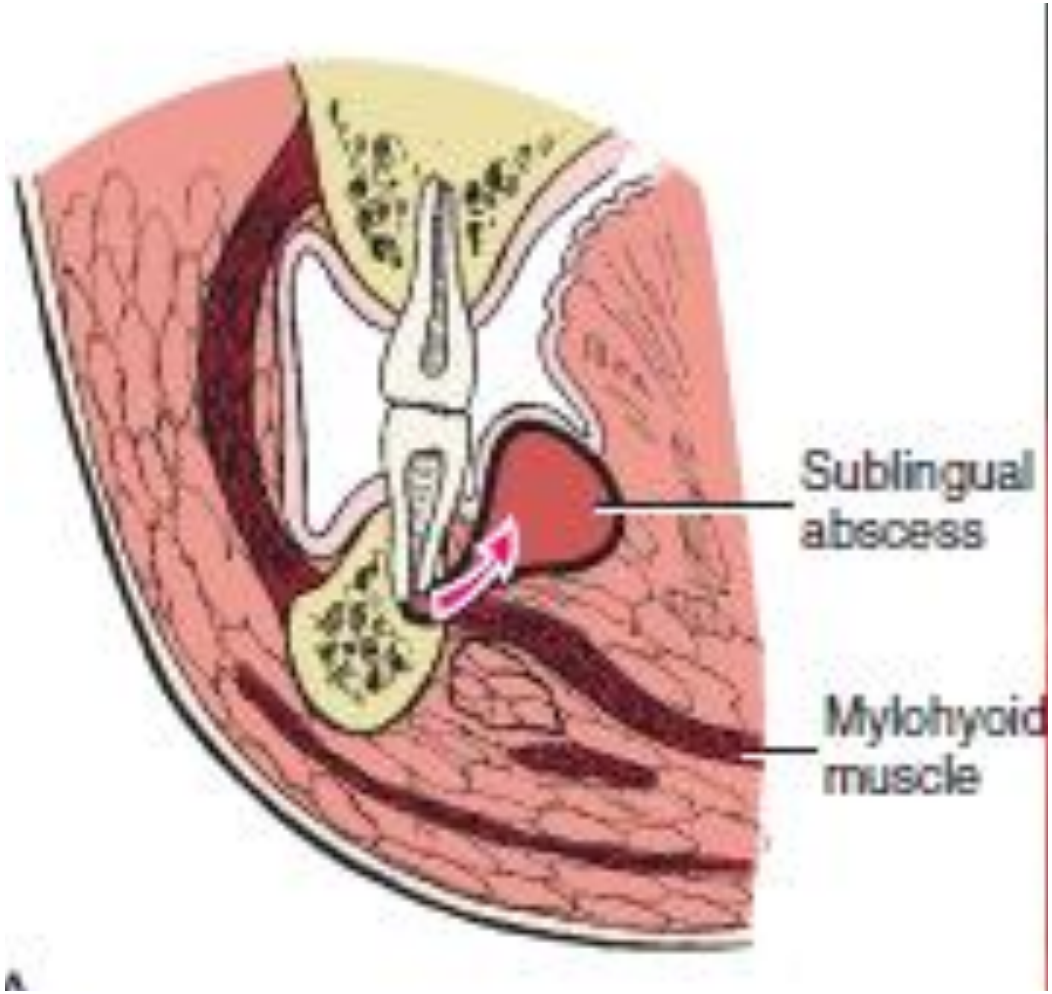

Submandibular vs. Sublingual

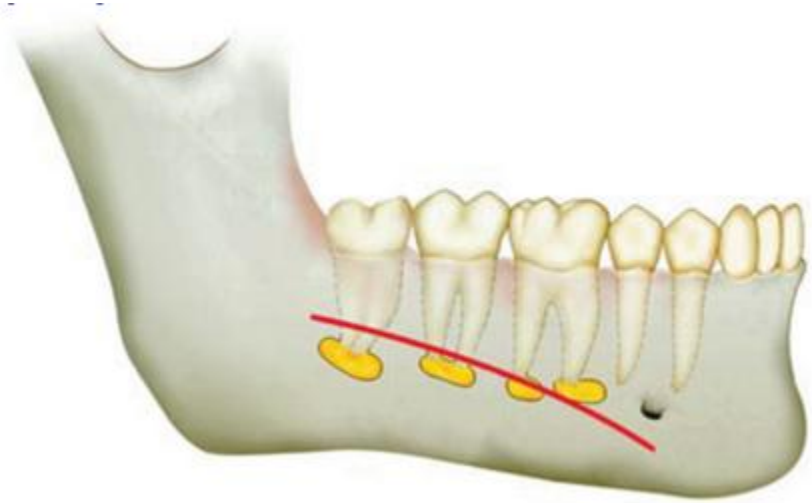

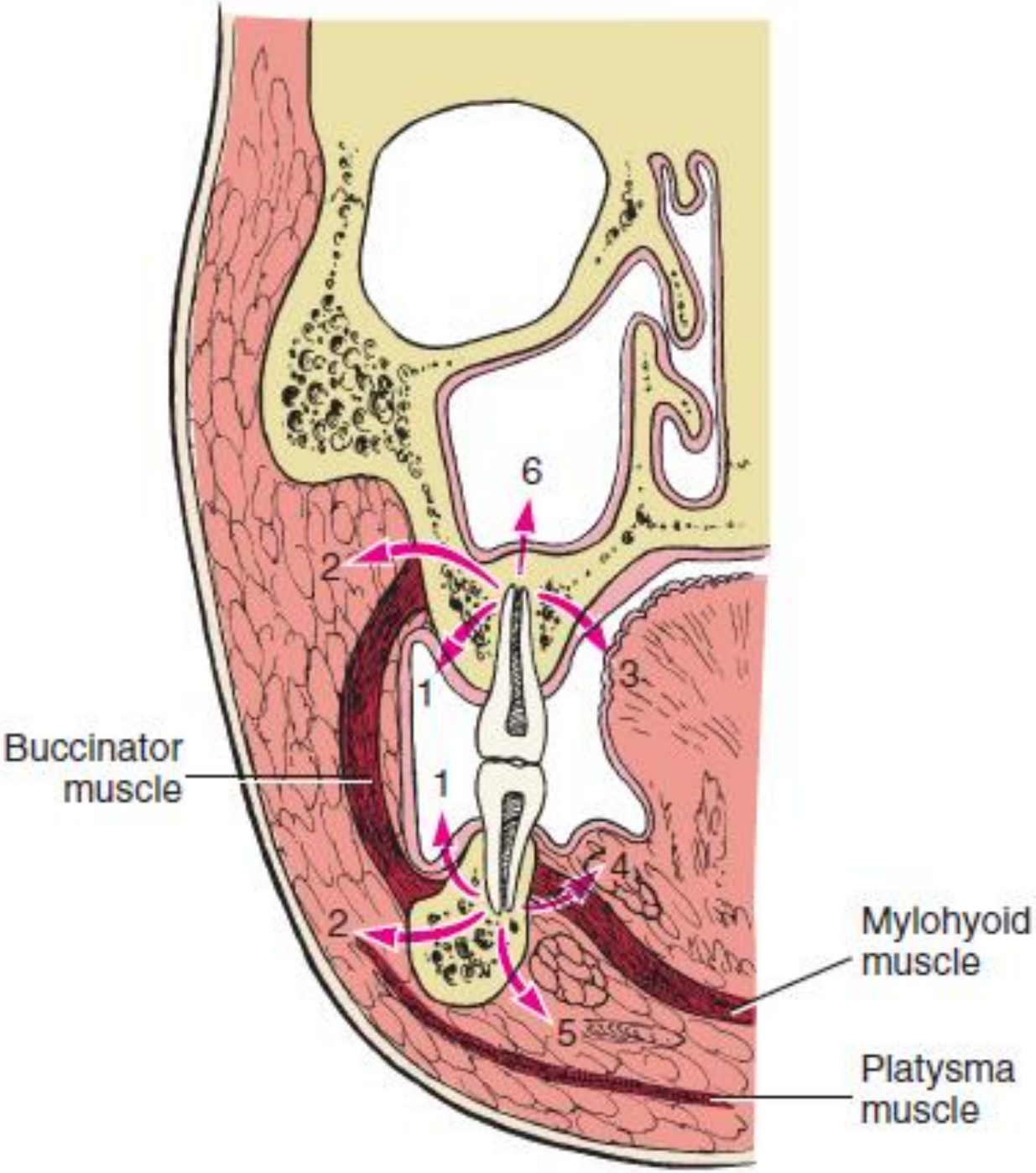
6
2
1
3
Buccinator muscle
1
4
2
Mylohyoid muscle
5
Platysma muscle

Infraorbital

- Bounded by the oral mucosa, nasal cartillages, buccal space (as well as several muscles of facial expression).
- Origin is usually maxillary canines.
- Drained through an intraoral incision.

Incision and Drainage Left Canine Space

- Incise
- Irrigate
- Place and suture ¼ inch Penrose

- Perform excision of lesion
- Undermine tissue and suture

- Describe anesthetic Technique
- Explain potential risks (V2)

Palatal

- Origin is upper lateral incisors.
- Drained through an intraoral incision.
- Never incise through the palatal mucosa distal to the premolars.

Temporal Spaces

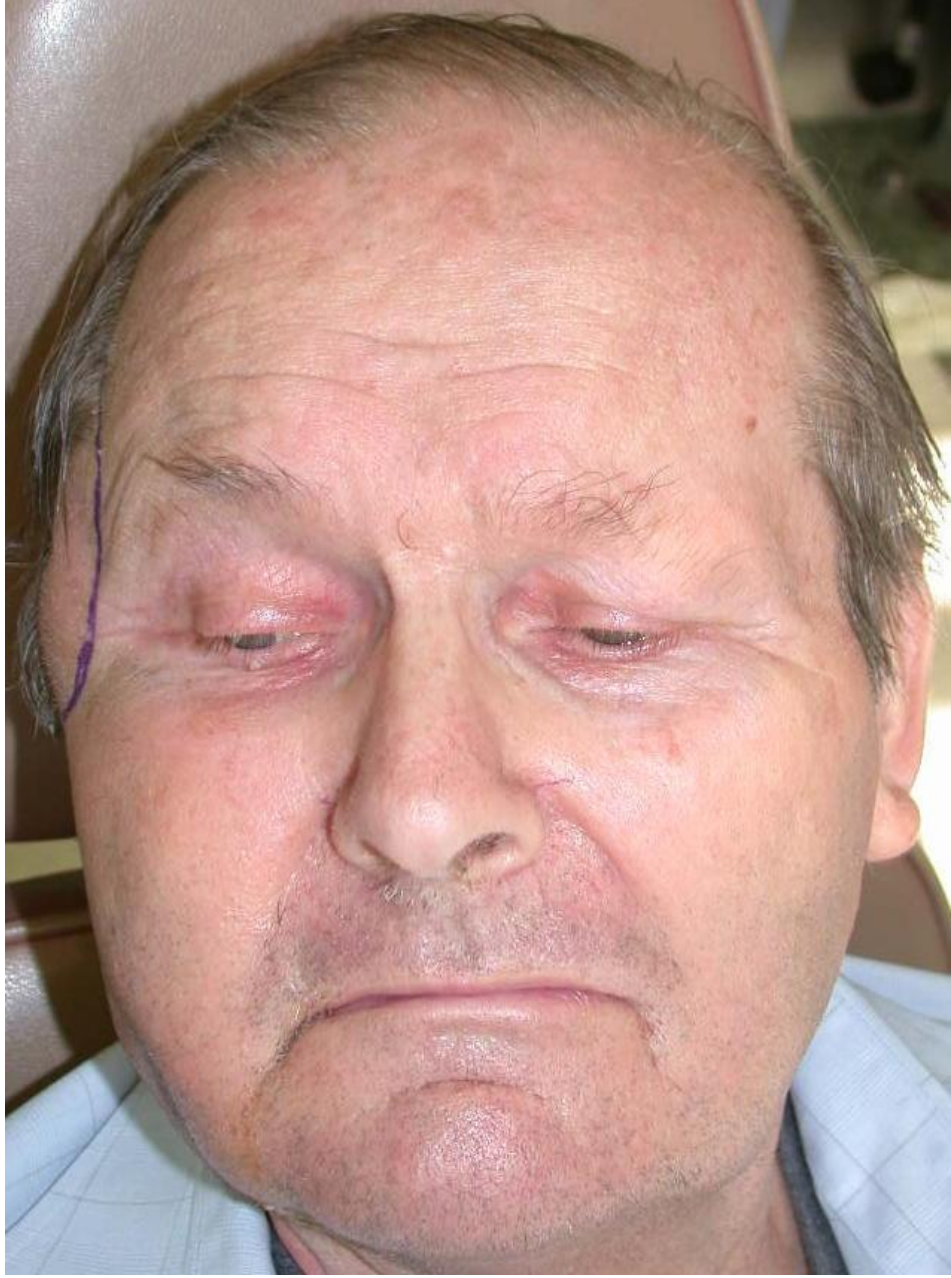

“Unconventional” Infections

- Actinomycosis.
- Tuberculosis.
- Necrotizing fasciitis.
- Etc.

Complications Of Untreated Or Improperly Treated Infections

- Septic shock.
- Mediastinitus.
- Massive haemorrhage secondary to erosion of great vessels.
- Metastatic abscess.
- Orbital extension and blindness.
- Intra-cranial venous sinus involvement.

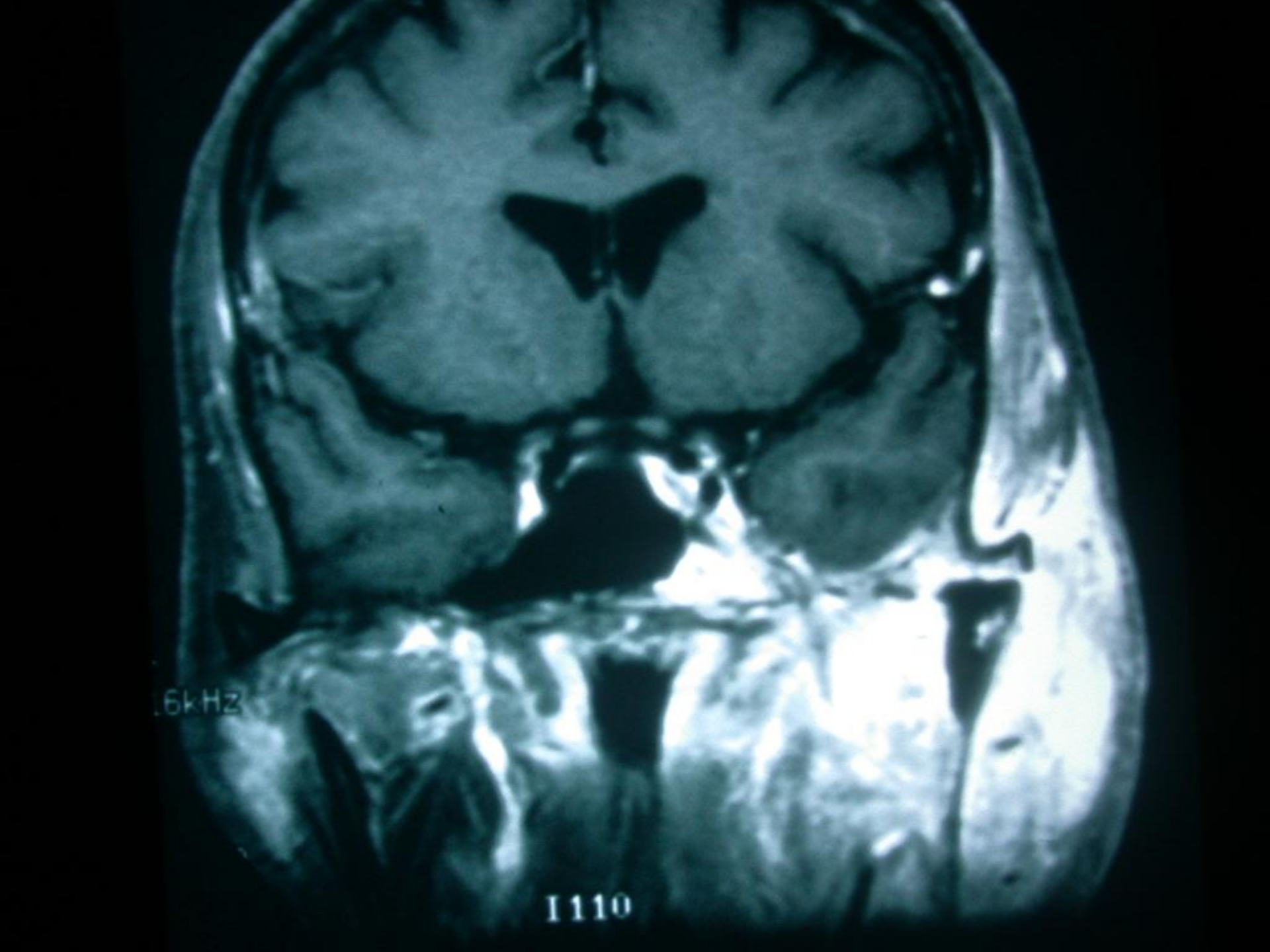
.6kHz
1110

SATURDAY STAR

SHOWERS. HIGH 13C (NORMAL IS 14.3C) ★ APRIL 28, 2007 ★ thestar.com

HOW COULD A TOOTHACHE LEAD TO BLINDNESS?

Unaffordable dental care has extracted a terrible price from Moses Han and his family

Charity tax dodg entangle parish

STAR INVESTIGATION: Thous donors audited after firm issue in bogus receipts in church's n

KEVIN DONOVAN
STAFF REPORTER

A small Greek Orthodox church in Toronto has been hijacked by a fundraising company that used the church's good name to issue $273 million in apparently phoney charitable tax receipts over the past five years.

It's part of a dubious tax shelter scheme cooked up by a Concord, Ont., company that promised to spread relief to the world. Some medical supplies, comics and crayons were distributed,

Giving Trust" created by th Arvanitis, new vice-p with a finan proportion sifting thr boxes of ceipts. B company the-chu tax re Use w been 200 20

WHEN TO REFER INFECTED PATIENTS

When to Refer Infected Patients

- Inferior border not palpable.
- Ophthalmic or Neurologic changes.
- Eye swollen.
- Patient does not respond to appropriate antibiotic therapy.
- Patient with multiple drug allergies and you’re not sure what to prescribe.

When to Refer Infected Patients

- Dysphagia.
- Dyspnea.
- Visible swelling of the pharynx.
- Profound trismus.
- Swelling near skin.
- Obvious necrosis.